

Corso di formazione CEAV

Padova, 12 ottobre 2017

Immunoncologia e tumori coloretali

Sara Lonardi, MD

SS Neoplasie gastroenteriche - UOC Oncologia Medica 1

Dipartimento di Oncologia Clinica e Sperimentale

Istituto Oncologico Veneto – IRCCS, Padova



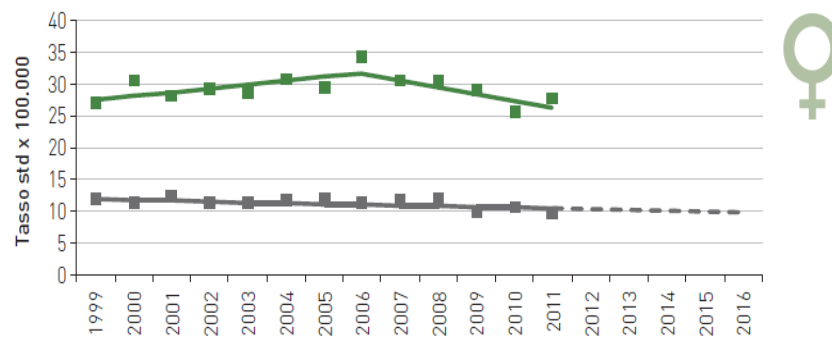
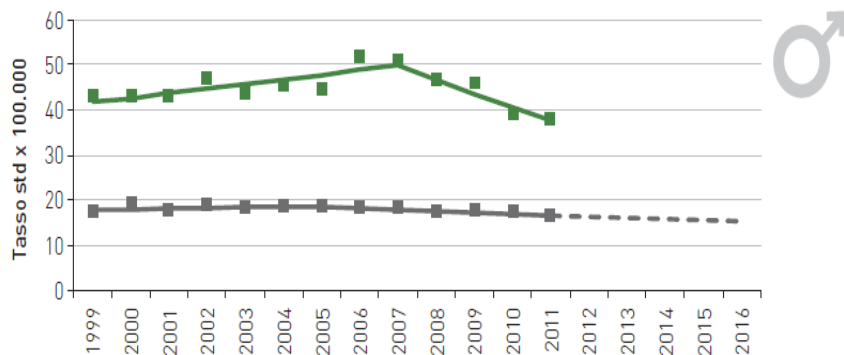
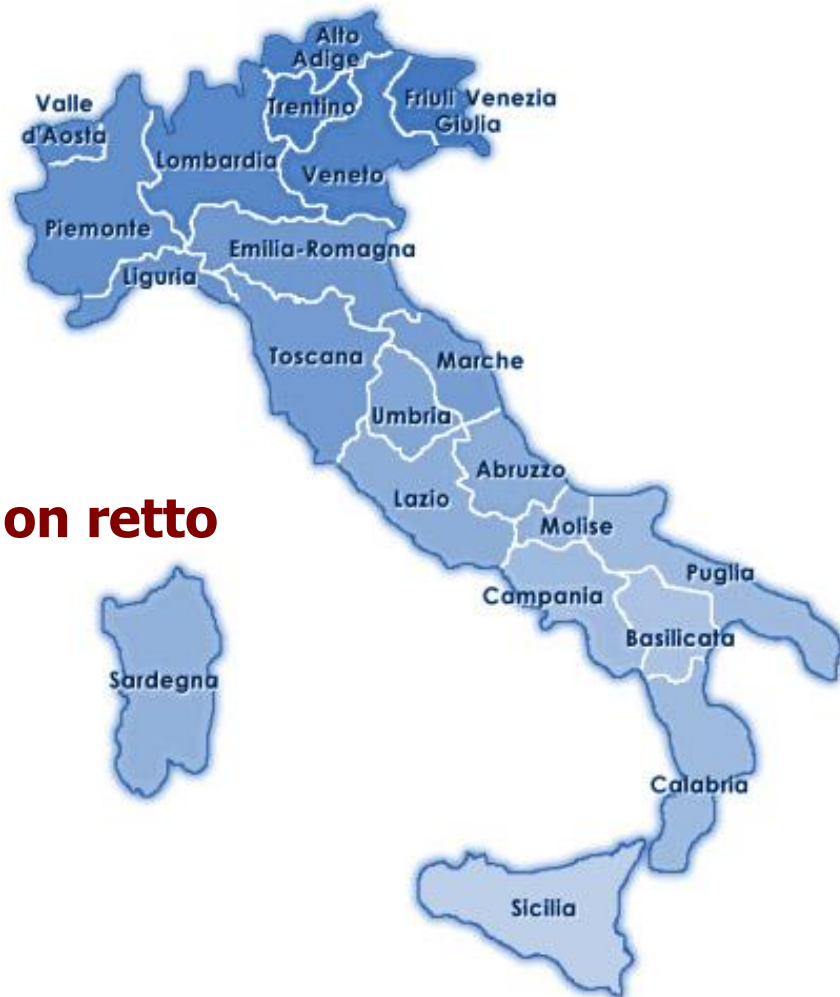Regione del Veneto

Situazione in Italia

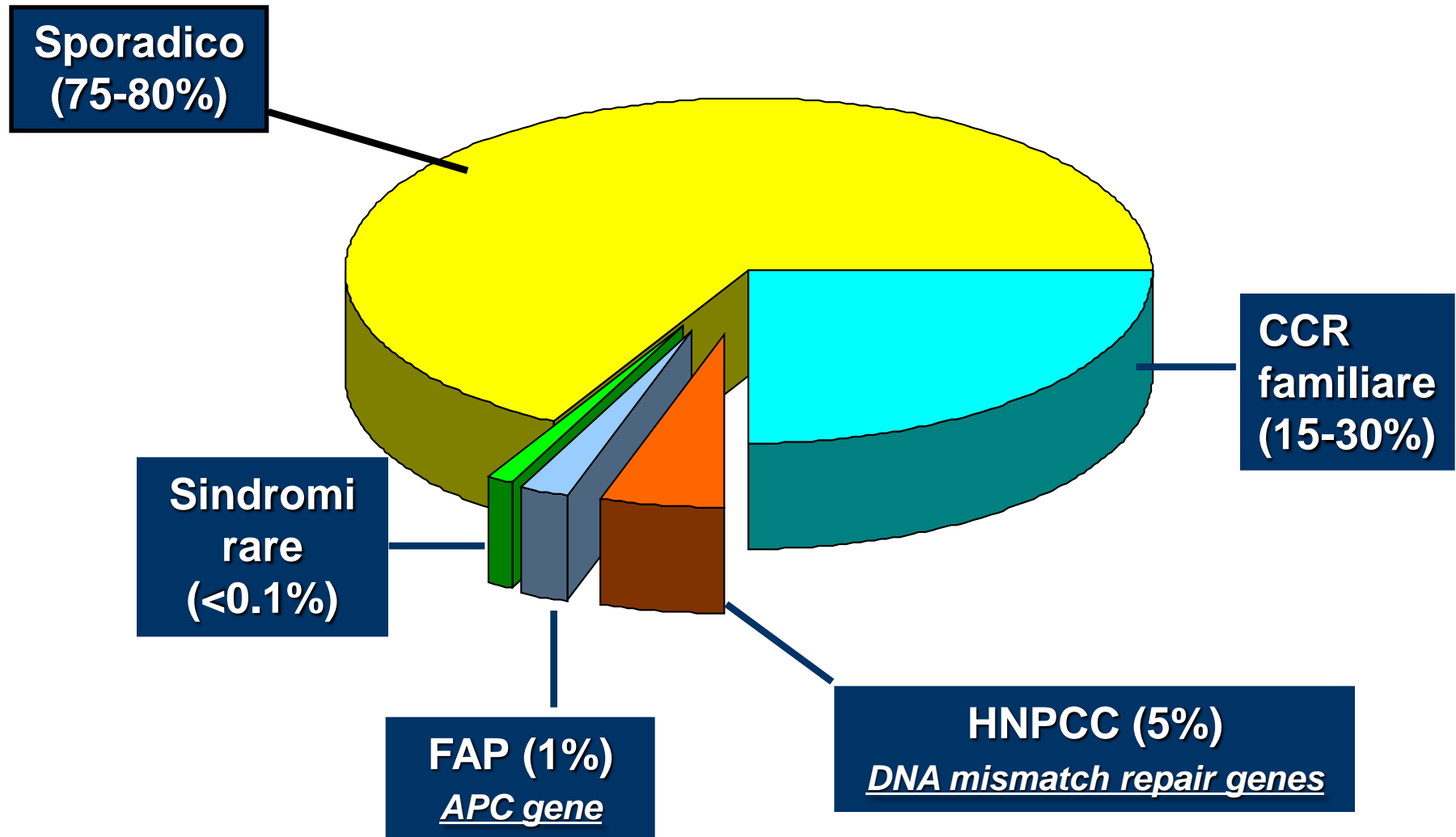
Circa 40.000 nuovi casi all'anno

Circa 20.000 morti all'anno


Il rischio di ammalarsi di **cancro del colon retto** nel corso dell'intera vita per un cittadino italiano è del **5–6 %**



Cancro colorettaie: eziologia



Eziologia multifattoriale



Età e sesso

Dieta e lifestyle

Familiarità

Sindromi

Anamnesi personale

5-y Survival by Stage

AJCC/ UICC	%
Stadio 0	100
Stadio I	100 (T1) 85 (T2)
Stadio II	65-55
Stadio III	55-25
Stadio IV	3-5

ADVANCED COLORECTAL CANCER META-ANALYSIS PROJECT

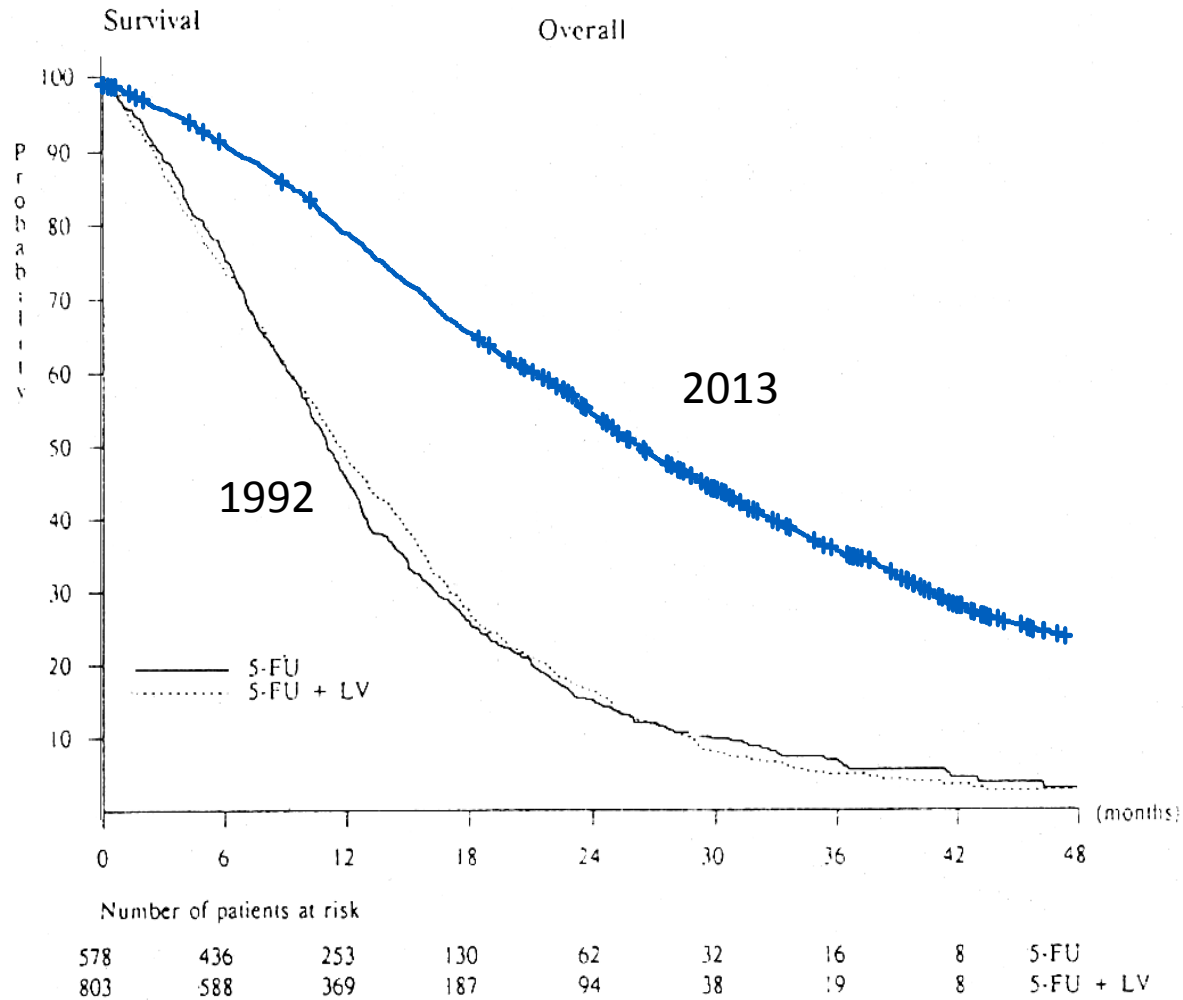
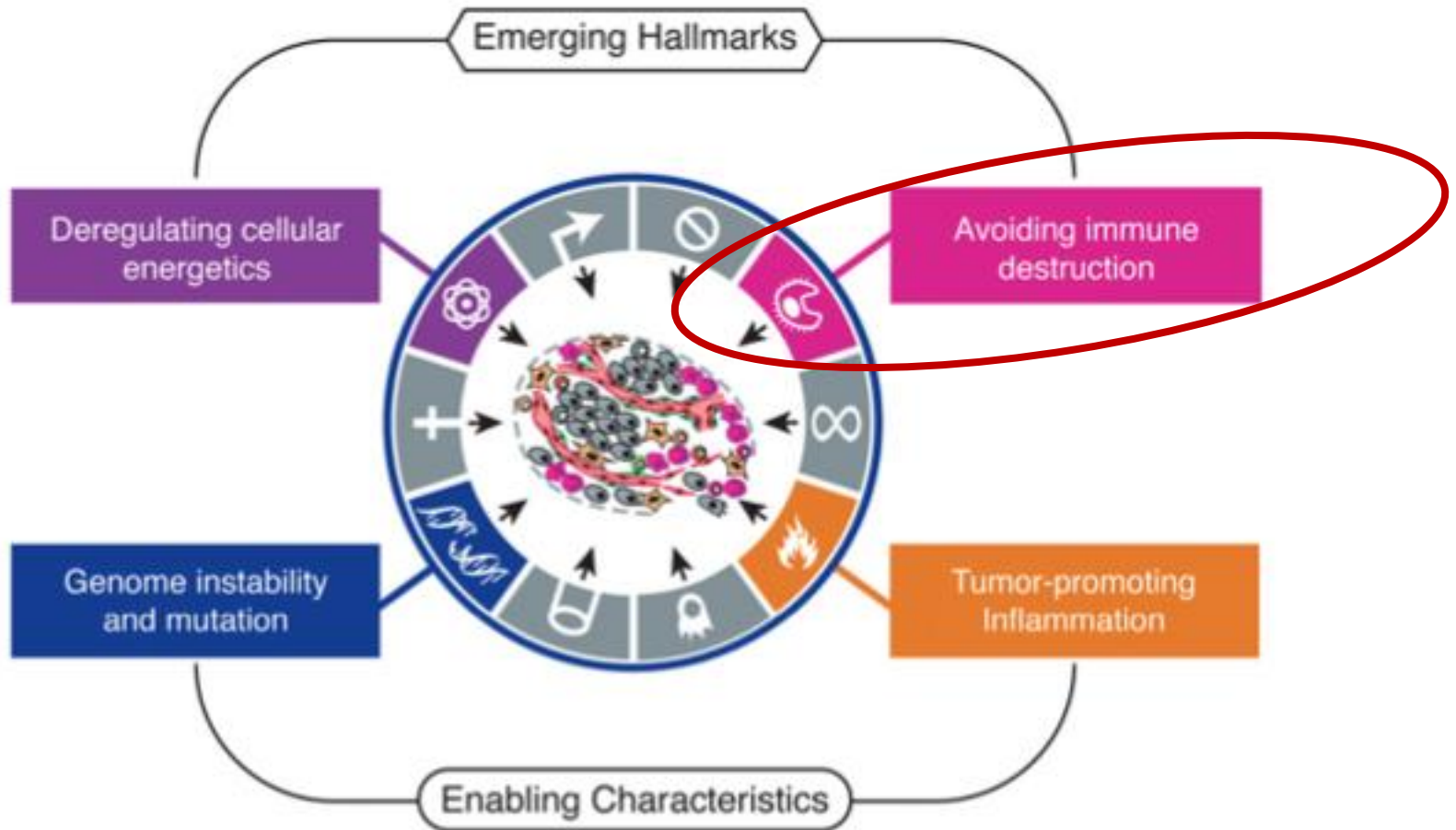


Fig 2. Overall survival.

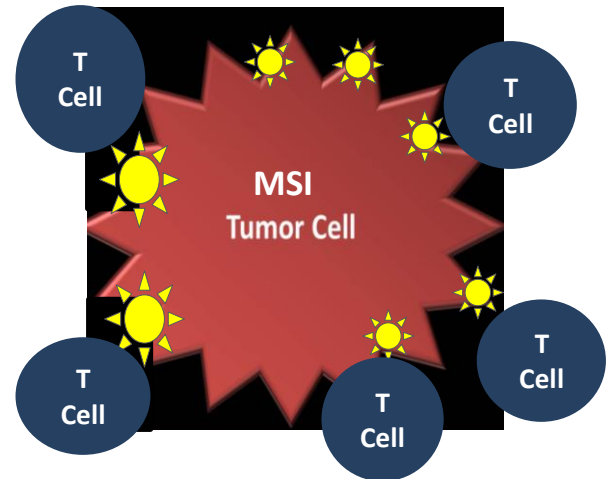
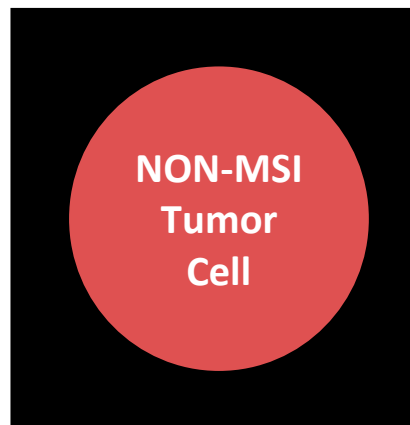


2011 Hallmarks of Cancer



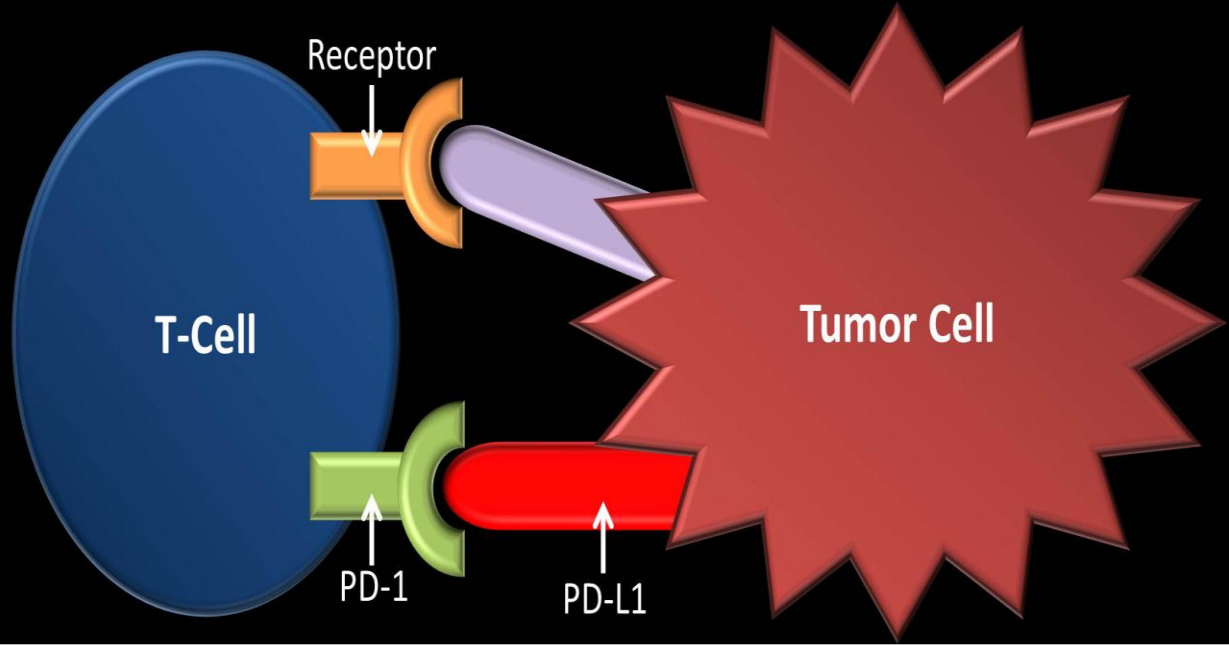
Microsatellite instability in mCRC

- Microsatellite instable cancers (MSI-H) have a defect in repairing DNA resulting in a very high mutation rate
- Higher number of neoantigens in MSI-H tumors attracts tumor-infiltrating lymphocytes (TILs) and overexpression of programmed death-1 (PD-1) and PD-1 ligand 1 (PD-L1) which inhibits tumor cell killing



- **MSI-H status is found in approximately 4% of metastatic CRC**

Tumor Killing



Where it all started

ORIGINAL ARTICLE

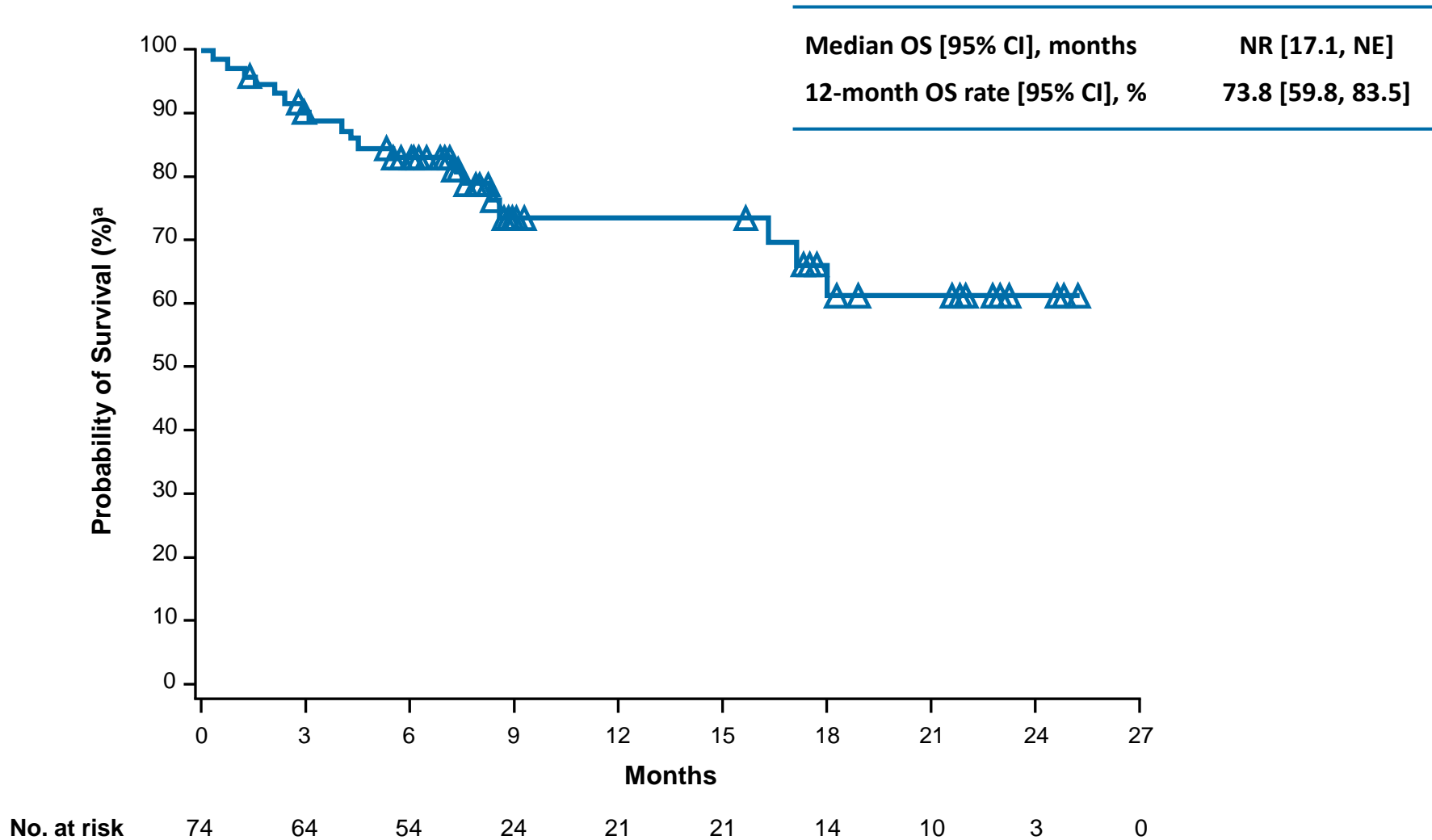
PD-1 Blockade in Tumors with Mismatch-Repair Deficiency

Type of response	MSI (n=10)	MSS (n=18)
Complete Response	0%	0%
Partial Response	40%	0%
Objective Response Rate	40%	0%
Disease Control Rate	90%	11%

Just Published

Nivolumab in Patients With DNA Mismatch Repair Deficient/Microsatellite Instability High Metastatic Colorectal Cancer: First Results From CheckMate 142

Overall Survival



Safety

Patients, n (%)	All Patients (N = 74)	
	Any grade	Grade 3–4
Any TRAE	51 (68.9) ^a	15 (20.3)
TRAEs reported in ≥ 10% of patients		
Fatigue	17 (23.0)	1 (1.4)
Diarrhea	16 (21.6)	1 (1.4)
Pruritus	10 (13.5)	0
Lipase increased	9 (12.2)	6 (8.1)
Rash	8 (10.8)	0

AP, the first patient treated at IOV-IRCCS

AP, the first patient treated at IOV-IRCCS

Dicembre 2013:

**emicolectomia destra palliativa con riscontro
intraoperatorio di noduli peritoneali**

Adenocarcinoma G3 di tipo mucinoso, R2

pT4a N2b(7/10) M1b(peritoneo) – Stadio IVB

KRAS mut G12D

First and second-line chemotherapy



FOLFIRI – Bevacizumab
12 cicli

dopo 4 cicli ↓

PR

TVP

sospeso Bev

↓

PD (peritoneo)



FOLFOX
8 cicli

dopo 4 cicli ↓

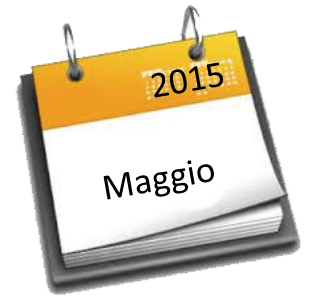SD

↓

PD (peritoneo, linfonodi addominali)

Valutazione allo IOV-IRCCS per inclusione in trial clinico

PRIMA VISITA ONCOLOGICA PRESSO IOV



- **Anemizzazione molto frequente con necessità di trasfusioni 1-2 volte alla settimana**
- **Dolore mal controllato con oppioidi a dosi elevate**
- **Calo ponderale di oltre 15 kg negli ultimi 6 mesi**
- **Depressione reattiva**

Analisi molecolare del profilo microsatellitare

Analisi dell'instabilità dei microsatelliti

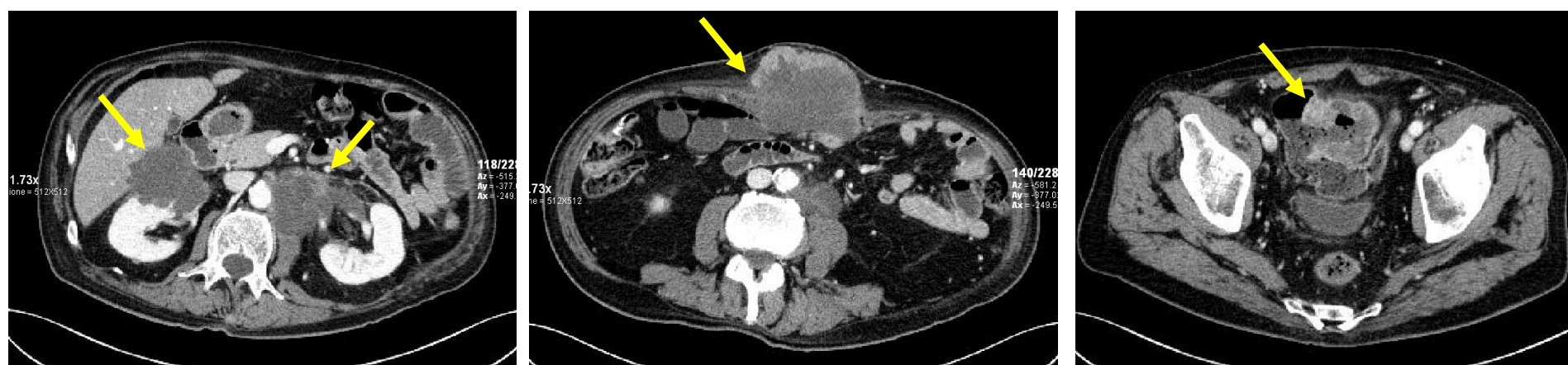BAT25 (cromosoma 4; locus 4q12)	Non alterato
BAT26 (cromosoma 2; locus 2p22)	Alterato
D2S123 (cromosoma 2; locus 2p16)	Non alterato
D5S346 (cromosoma 5; locus 5q21-q22)	Non alterato
D17S250 (cromosoma 17; locus 17q11.2)	Alterato

L'analisi molecolare effettuata su campione di DNA ottenuto da tessuto neoplastico ha evidenziato un pattern elettroforetico non sovrapponibile a quello del tessuto normale per 2 su 5 marcatori utilizzati. Il quadro osservato indica un profilo di Alta Instabilità.

Arruolamento in protocollo CheckMate 142

- ▶ 26/05/2015: Arruolamento **Protocollo CA209-142**
- ▶ Braccio di trattamento: **cStage1**
Ipilimumab (3 mg/kg) + Nivolumab (1 mg/Kg) q3w x 4 cicli
⇒ **Nivolumab (3 mg/Kg) q2w**

TC BASALE:

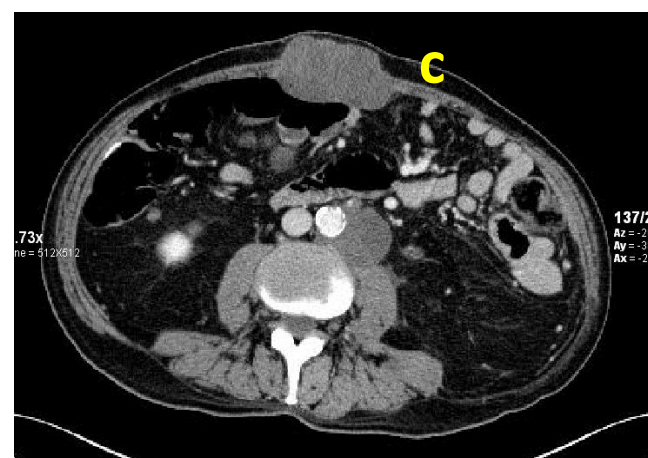
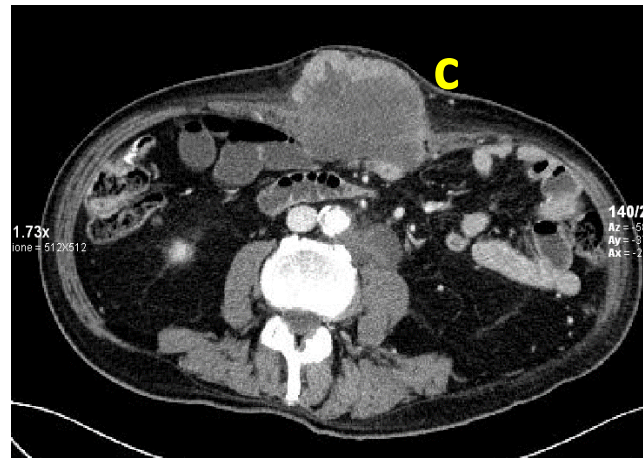
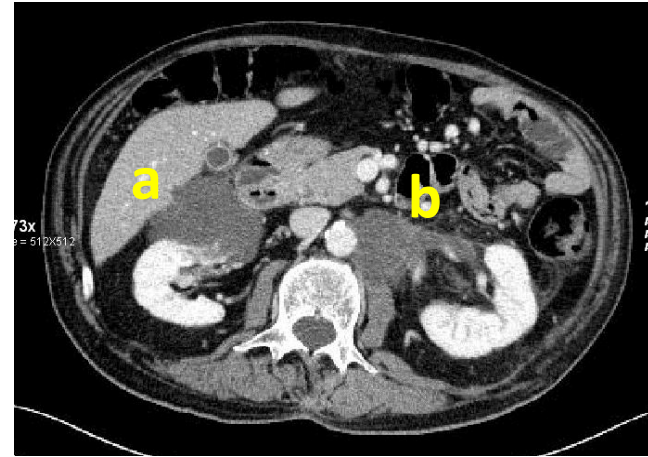
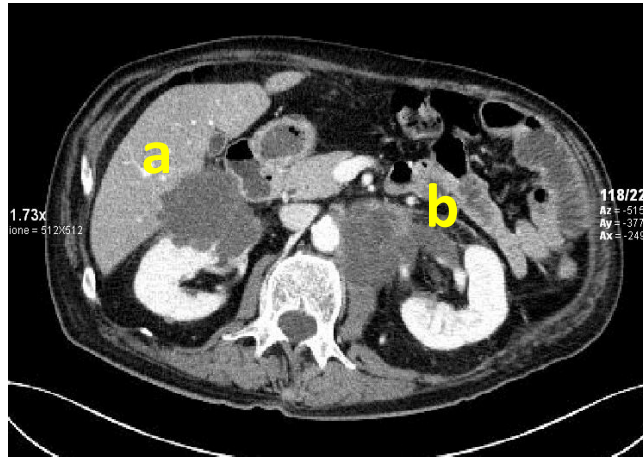


Risposta al trattamento dopo soli 2 mesi

TC basale



Dopo 4 cicli di terapia

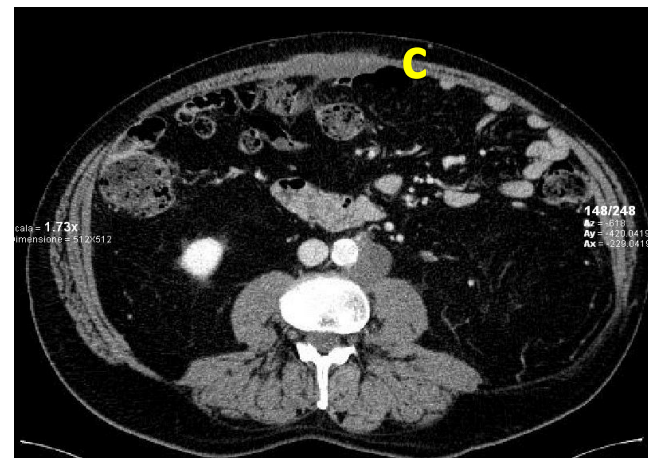
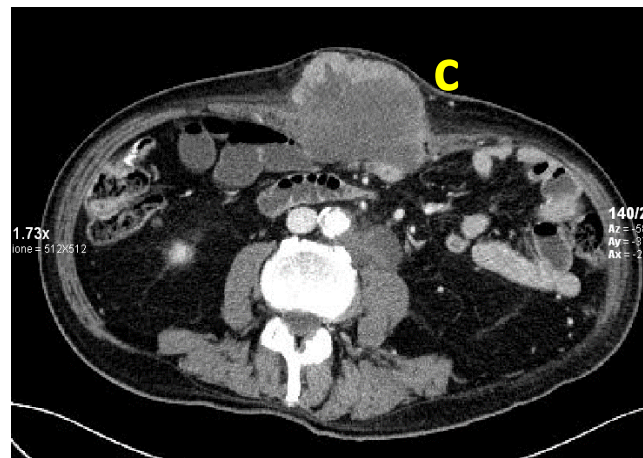
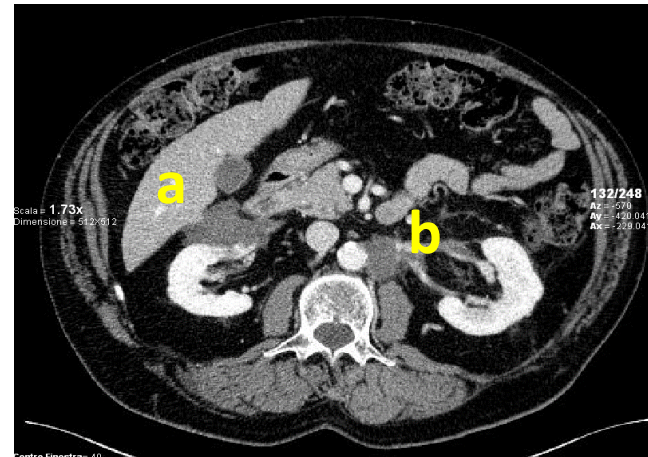
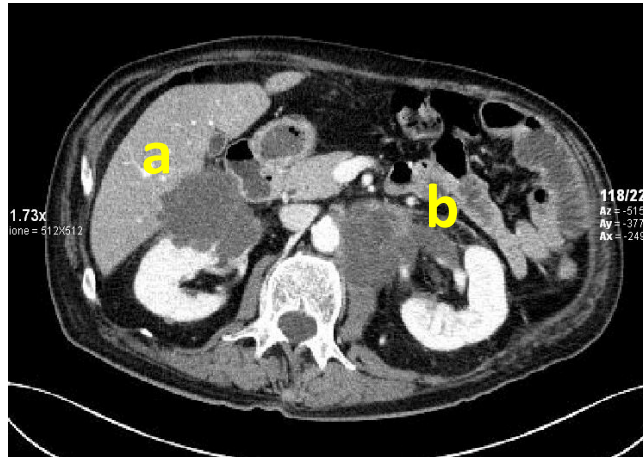


Risposta al trattamento dopo 8 mesi

TC basale



Dopo 28 cicli di terapia



Evoluzione clinica

- ❑ **Pieno recupero del Performance Status**
- ❑ **Completo recupero ponderale (19 Kg in 12 mesi)**
- ❑ **Sospensione completa della terapia antalgica**
- ❑ **Normalizzazione dei valori emoglobinici**
- ❑ **Ripresa di una vita familiare e sociale pienamente attiva**

Trattamento con Nivolumab ongoing da oltre 28 mesi

Future perspectives

- ❑ **Utilizzo in linee più precoci di trattamento**
- ❑ **Associazione con altri trattamenti per prevenire la resistenza**
- ❑ **Identificazione di altri sottogruppi di pazienti che ne possano beneficiare**

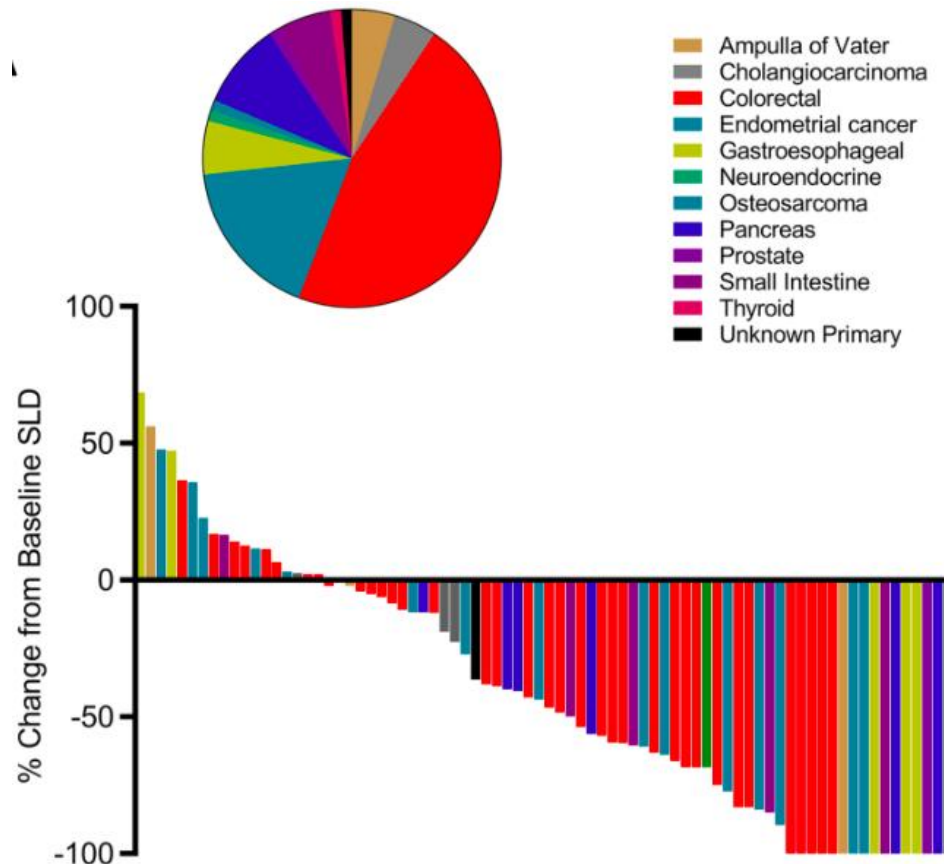
Confirmatory Results

Science

REPORTS

Cite as: D. T. Le *et al.*, *Science*
10.1126/science.aan6733 (2017).

Mismatch-repair deficiency predicts response of solid tumors to PD-1 blockade



Le *et al.*, *Science* 2017

A new era

The image is a screenshot of the FDA website. At the top, it displays the U.S. Department of Health and Human Services logo and the FDA logo. The main navigation bar includes links for Home, Food, Drugs, Medical Devices, Radiation-Emitting Products, Vaccines, Blood & Biologics, Animal & Veterinary, Cosmetics, and Tobacco Products. A search bar is located on the right side. Below the navigation bar, the page is titled "Drugs" and shows a breadcrumb trail: Home > Drugs > Drug Approvals and Databases > Approved Drugs. The main content area features a blue header for "Approved Drugs" and a sub-header for "Hematology/Oncology (Cancer) Approvals & Safety Notifications". The primary headline reads: "FDA grants accelerated approval to pembrolizumab for first tissue/site agnostic indication".

U.S. Department of Health and Human Services

FDA U.S. FOOD & DRUG ADMINISTRATION

A to Z Index | Follow FDA | En Español

Search FDA

Home | Food | Drugs | Medical Devices | Radiation-Emitting Products | Vaccines, Blood & Biologics | Animal & Veterinary | Cosmetics | Tobacco Products

Drugs

Home > Drugs > Drug Approvals and Databases > Approved Drugs

Approved Drugs

Hematology/Oncology (Cancer) Approvals & Safety Notifications

FDA grants accelerated approval to pembrolizumab for first tissue/site agnostic indication

www.fda.org accessed on May 23rd, 2017,